VENÖZ SİSTEM ANOMALİLERİ

Doç. Dr Aytül Çorbacıoğlu Esmer

Kanuni Sultan Süleyman Eğitim ve Araştırma Hastanesi
Perinatoloji Bölümü

29-31 Ekim 2015
Ulltrasonografi Kursu
Harbiye Askeri Müze

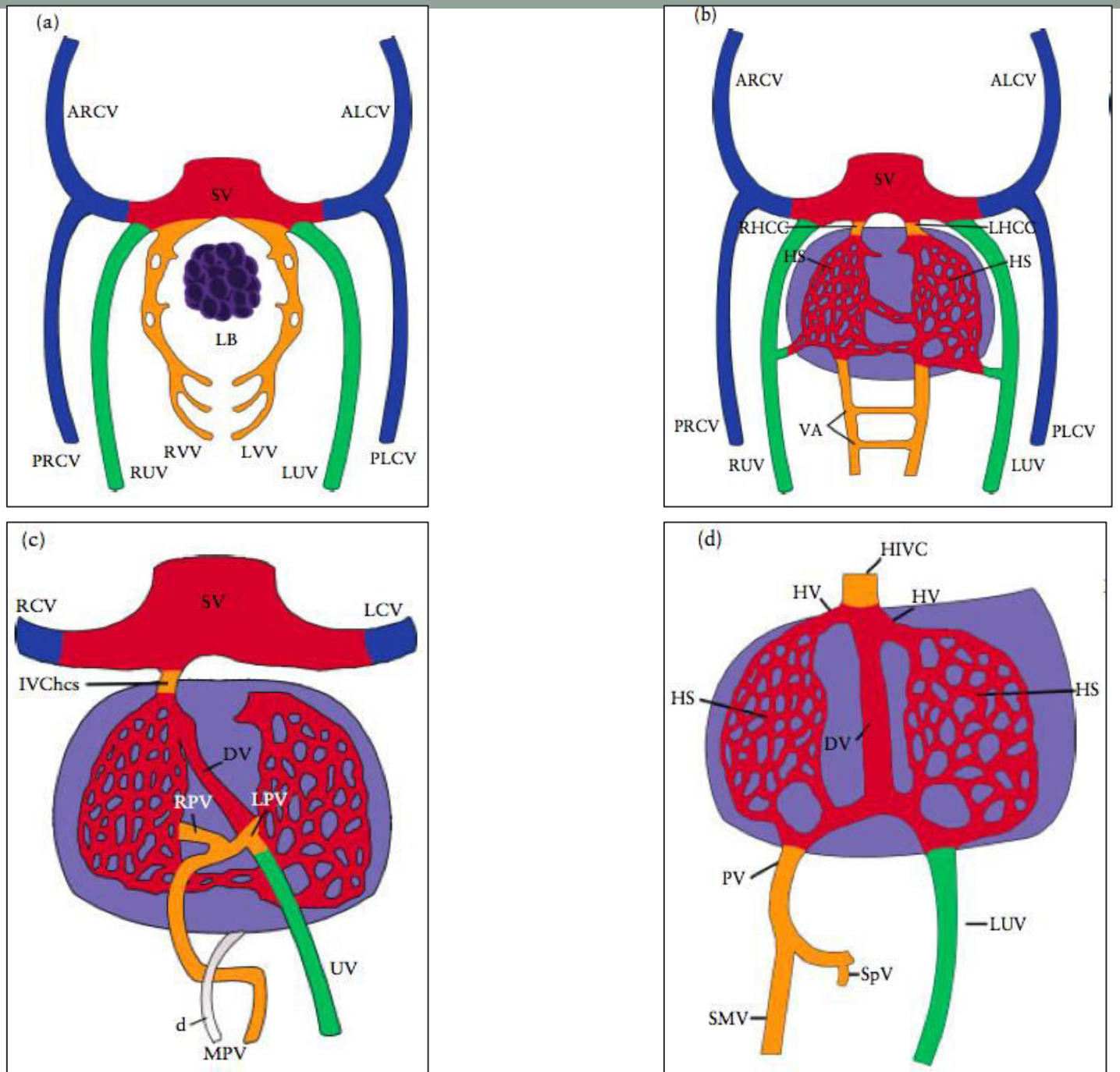
(a)
ARCV
ALCV
SV
LB
PRCV
RUV
RVV
LVV
LUV
PLCV
(b)
ARCV
ALCV
SV
RHCC
LHCC
HS
HS
PRCV
VA
PLCV
RUV
LUV
(c)
RCV
SV
LCV
IVChcs
DV
RPV
LPV
UV
d
MPV
(d)
HIVC
HV
HV
HS
HS
DV
PV
LUV
SpV
SMV

Classification

(A) Cardinal vein
  (a) Complex malformations, heterotaxic syndrome
  (b) Isolated malformation
(B) Anomalous pulmonary venous connection
  (a) Total
  (b) Partial
(C) Umbilical veins
  (a) Primary failure to create critical anastomoses
    (i) Complete: abnormal connection of umbilical vein (venous shunt) into iliac vein, inferior vena cava, superior vena cava and right atrium
    (ii) Partial: persistent right umbilical vein with or without ductus venosus
  (b) Secondary occlusion
(D) Vitelline veins

Duktus Venozus Agenezisi
Persistan Sağ Umbilikal Ven
Persistan Sol Vena Cava Superior

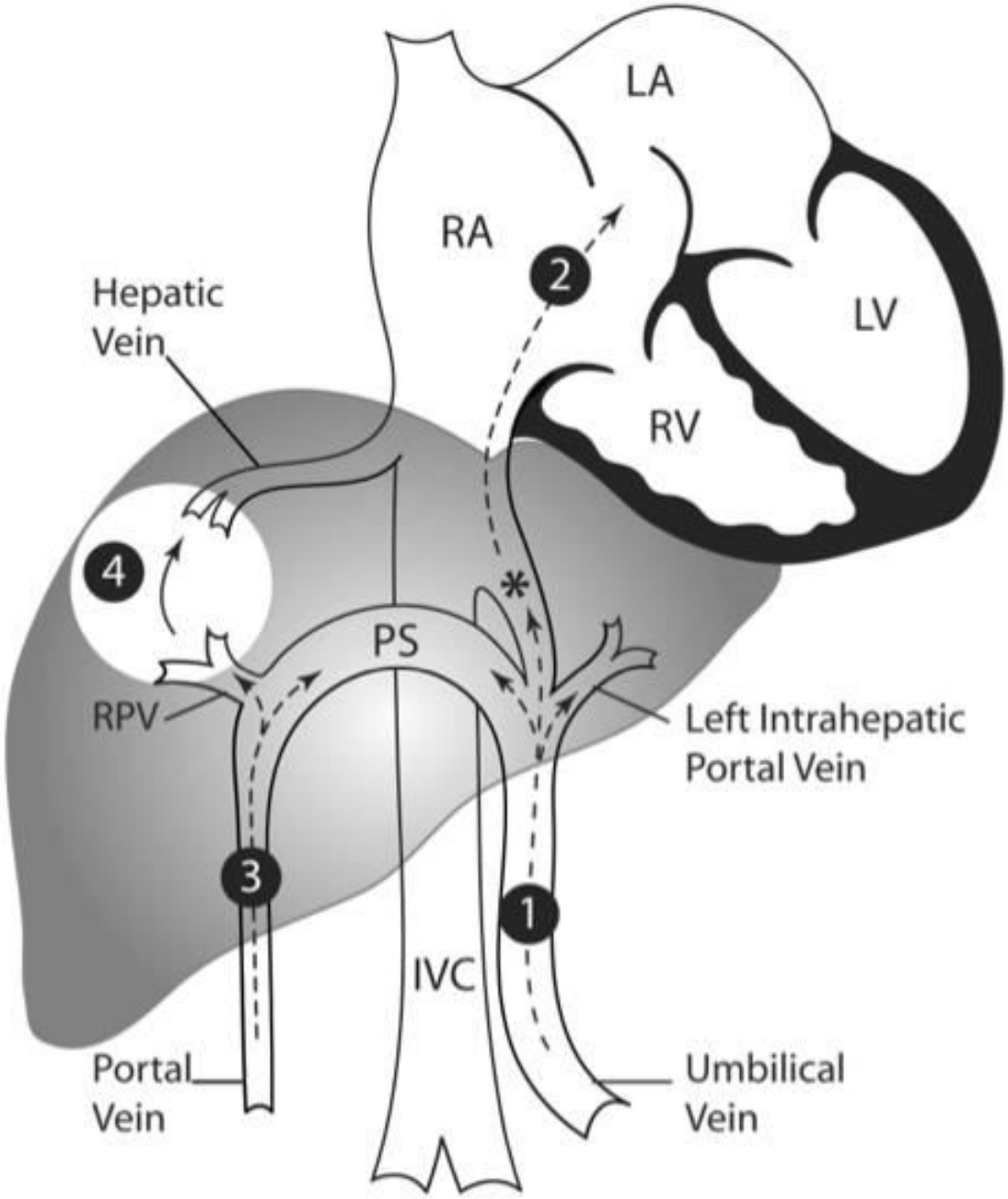
LA
RA
2
LV
RV
Hepatic
Vein
4
*
PS
RPV
Left Intrahepatic
Portal Vein
3
1
IVC
Portal
Vein
Umbilical
Vein

Voluson
E6

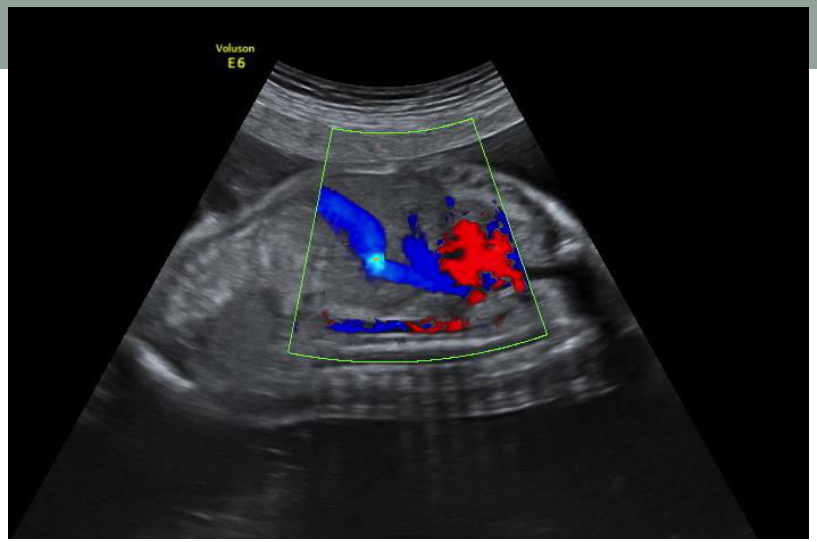
Voluson
E6

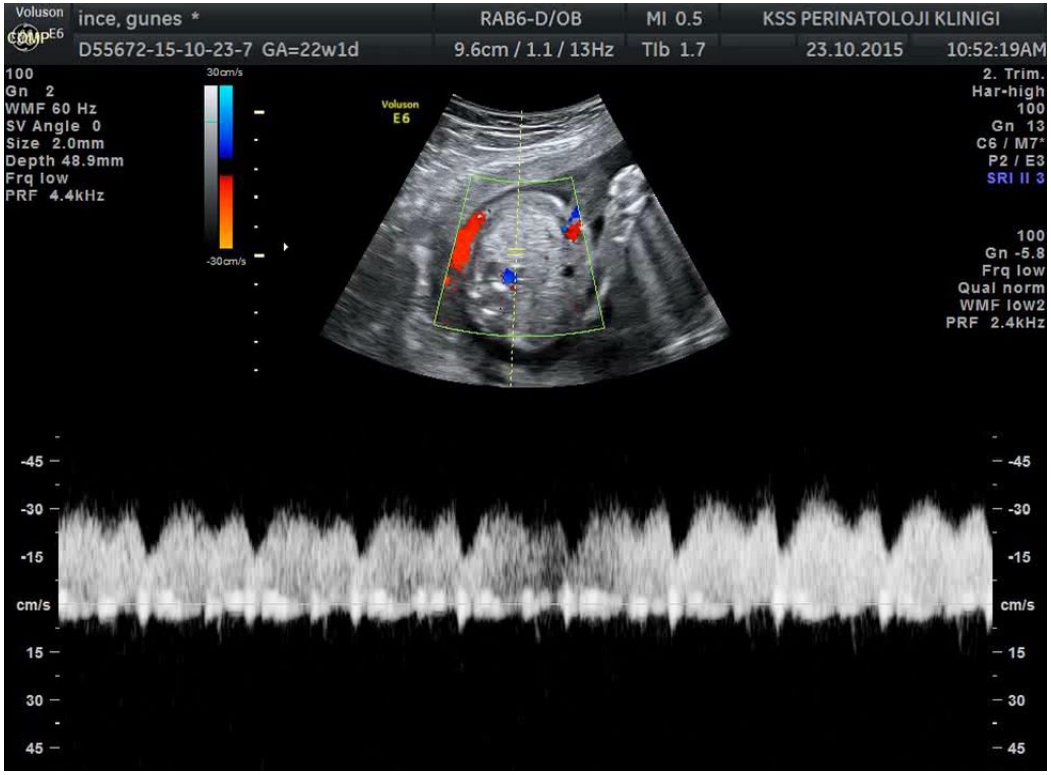
Voluson
E6
ince, gunes *
RAB6-D/OB
MI 0.5
KSS PERINATOLOJI KLINIGI
D55672-15-10-23-7 GA=22w1d
9.6cm / 1.1 / 13Hz
TIb 1.7
23.10.2015
10:52:19AM
100
Gn 2
WMF 60 Hz
SV Angle 0
Size 2.0mm
Depth 48.9mm
Frq low
PRF 4.4kHz
30cm/s
-30cm/s
2. Trim.
Har-high
100
Gn 13
C6 / M7*
P2 / E3
SRI II 3
100
Gn -5.8
Frq low
Qual norm
WMF low2
PRF 2.4kHz
-45
-30
-15
cm/s
15
30
45

Duktus Venozus Agenezisi

- Prevalans: Fetusta 6/1000 (Acherman, J Ultrasound Med 2007)
- İki tipi:
  - Ekstrahepatik: Karaciğer by-pass edilir. Umbilikal ven aberan bir damara bağlanır:
    - İliak ven
    - IVC
    - SVC
    - Sağ atrium
    - Nadiren sol atrium ve koroner sinüs
  - İntrahepatik: UV DV'un dalını vermeden portal sinüs olarak devam eder.

Doganer, Bilge 29.01.1981 RAB4-8-D/OB MI 0.9 MEDICANA INT. ISTANBUL
995 GA=29w5d 11.5cm / 1.9 / 53Hz TIs 0.2 12.05.2014 18:21:09
COMP
Cardiac
Har-mid
100
Gn 2
C6 / M7
FF1 / E1
SRI II 5 / CRI 3

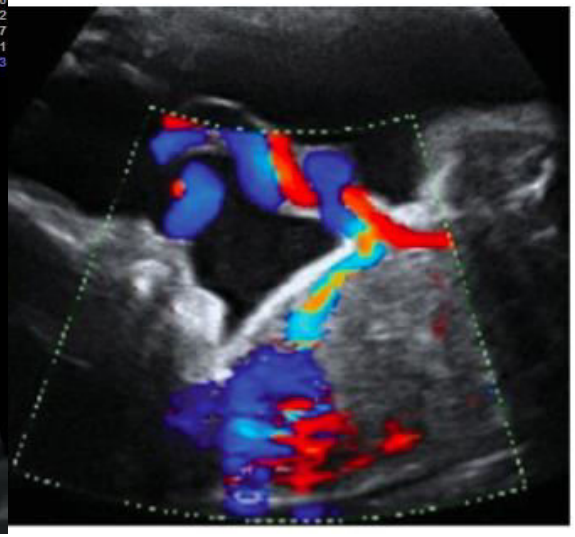

Doganer, Bilge 29.01.1981 RAB4-8-D/OB MI 1.2 MEDICANA INT. ISTANBUL
995 GA=31w6d 13.6cm / 1.5 / 34Hz TIs 0.1 27.05.2014 17:54:27
COMP
Anomaly
Har-low
100
Gn -2
C7 / M8
P3 / E1
SRI II 5

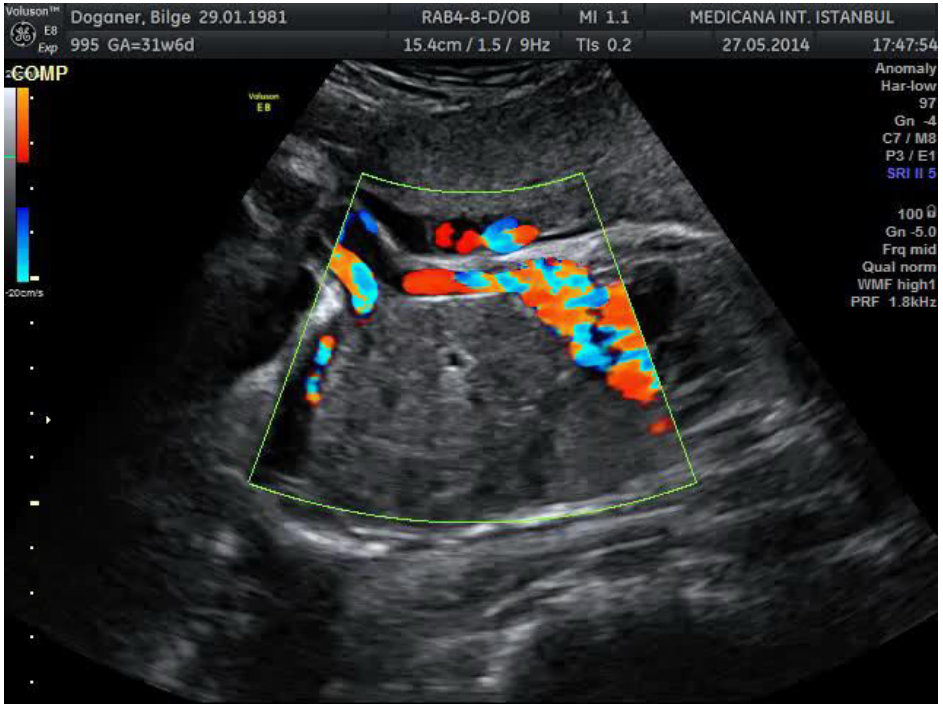
Doganer, Bilge 29.01.1981 RAB4-8-D/OB MI 1.1 MEDICANA INT. ISTANBUL
995 GA=31w6d 15.4cm / 1.5 / 9Hz TIs 0.2 27.05.2014 17:47:54
COMP
Anomaly
Har-low
97
Gn -4
C7 / M8
P3 / E1
SRI II 5
100
Gn -5.0
Frq mid
Qual norm
WMF high1
PRF 1.8kHz

Voluson
E6
korkutan, zeynep *
RAB6-D/OB
MI 1.1
KSS PERINATOLOJI KLINIGI
D55672-15-07-08-10 GA=21w6d
11.8cm / 1.3 / 15Hz
Tib 0.9
08.07.2015
3:43:07PM
30cm/s
-30cm/s
2. Trim.
Har-high
100
Gn 0
C6 / M7
P2 / E3
SRI II 3
100
Gn -5.8
Frq low
Qual norm
WMF low2
PRF 2.4kHz

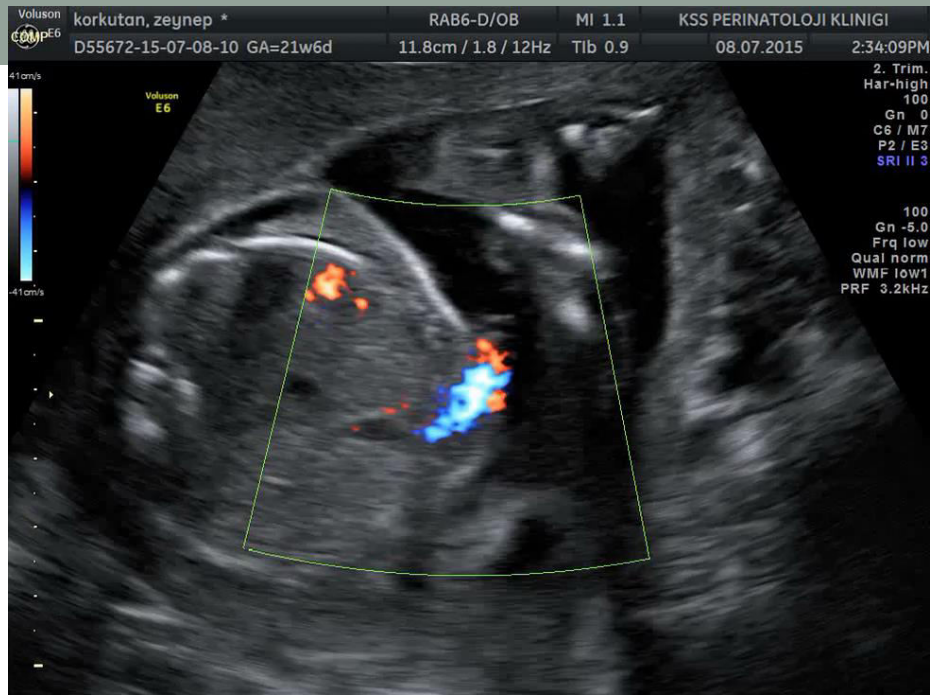
Voluson
E6
korkutan, zeynep *
RAB6-D/OB
MI 1.1
KSS PERINATOLOJI KLINIGI
D55672-15-07-08-10 GA=21w6d
11.8cm / 1.8 / 12Hz
Tib 0.9
08.07.2015
2:34:09PM
41cm/s
-41cm/s
2. Trim.
Har-high
100
Gn 0
C6 / M7
P2 / E3
SRI II 3
100
Gn -5.0
Frq low
Qual norm
WMF low1
PRF 3.2kHz

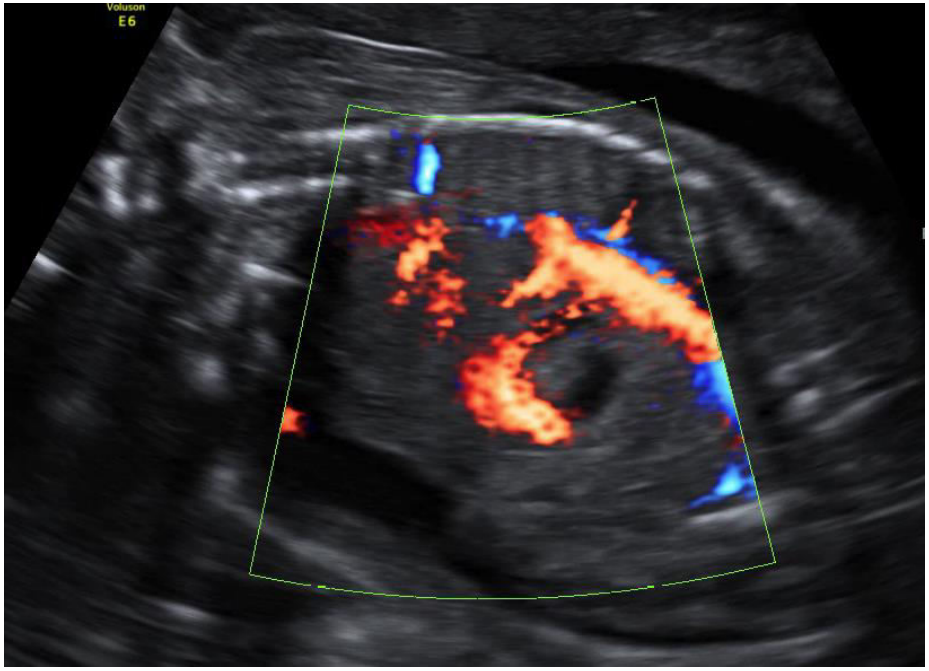
Voluson
E6

kiymetli, kalbiye
RAB 4-8L/OB
MI 1.0
ISTANBUL BAKIRKOY PERINATOL
41176-10-10-01-22
2.2/ 9.8cm / 16Hz
TIs 0.2
01.10.2010
15:33:23
COMP
Routine
Har-mid
Pwr 94 %
Gn -1
C7 / M7
P3 / E3
SRI II 3
Pwr 100 %
Gn -2.4
Frq low
Qual norm
WMF low1
PRF 0.9kHz

kiymetli, kalbiye
RAB 4-8L/OB
MI 1.0
ISTANBUL BAKIRKOY PERINATOL
41176-10-10-01-22
2.2/ 9.8cm / 16Hz
TIs 0.2
01.10.2010
15:33:23
COMP
Routine
Har-mid
Pwr 94 %
Gn -1
C7 / M7
P3 / E3
SRI II 3
Pwr 100 %
Gn -2.4
Frq low
Qual norm
WMF low1
PRF 0.9kHz

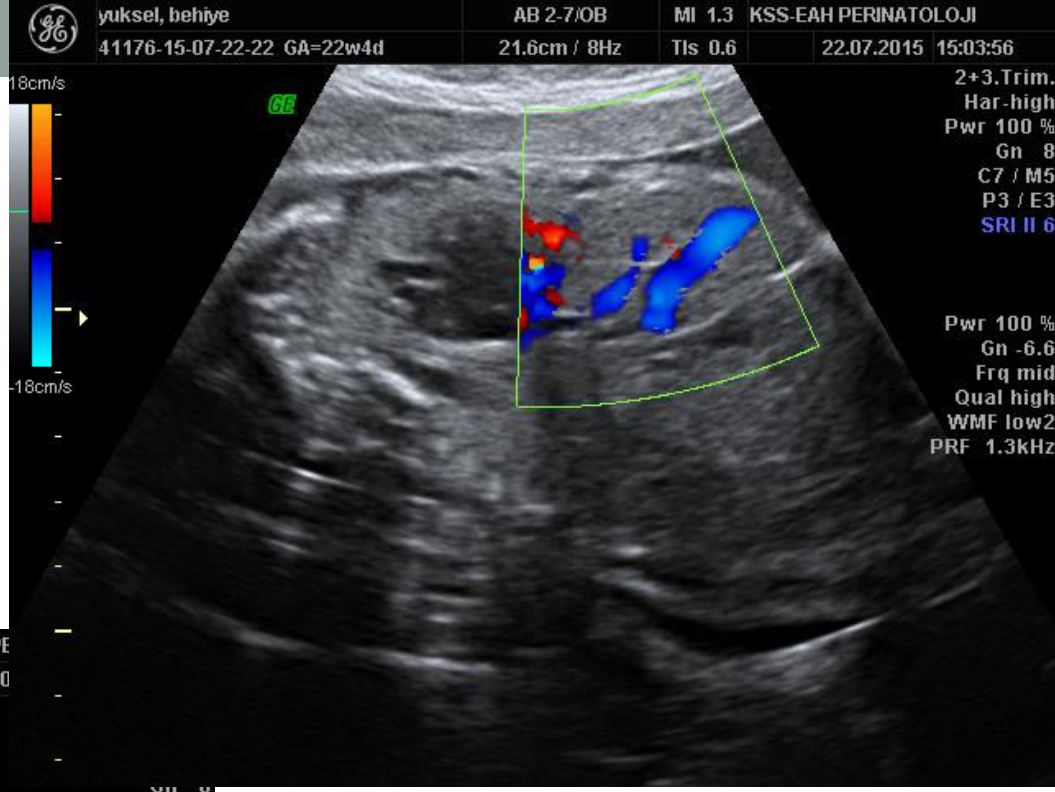
yuksel, behiye
AB 2-7/OB
MI 1.3
KSS-EAH PERINATOLOJI
41176-15-07-22-22 GA=22w4d
21.6cm / 8Hz
TIs 0.6
22.07.2015
15:03:56
18cm/s
-18cm/s
2+3.Trim.
Har-high
Pwr 100 %
Gn 8
C7 / M5
P3 / E3
SRI II 6
Pwr 100 %
Gn -6.6
Frq mid
Qual high
WMF low2
PRF 1.3kHz

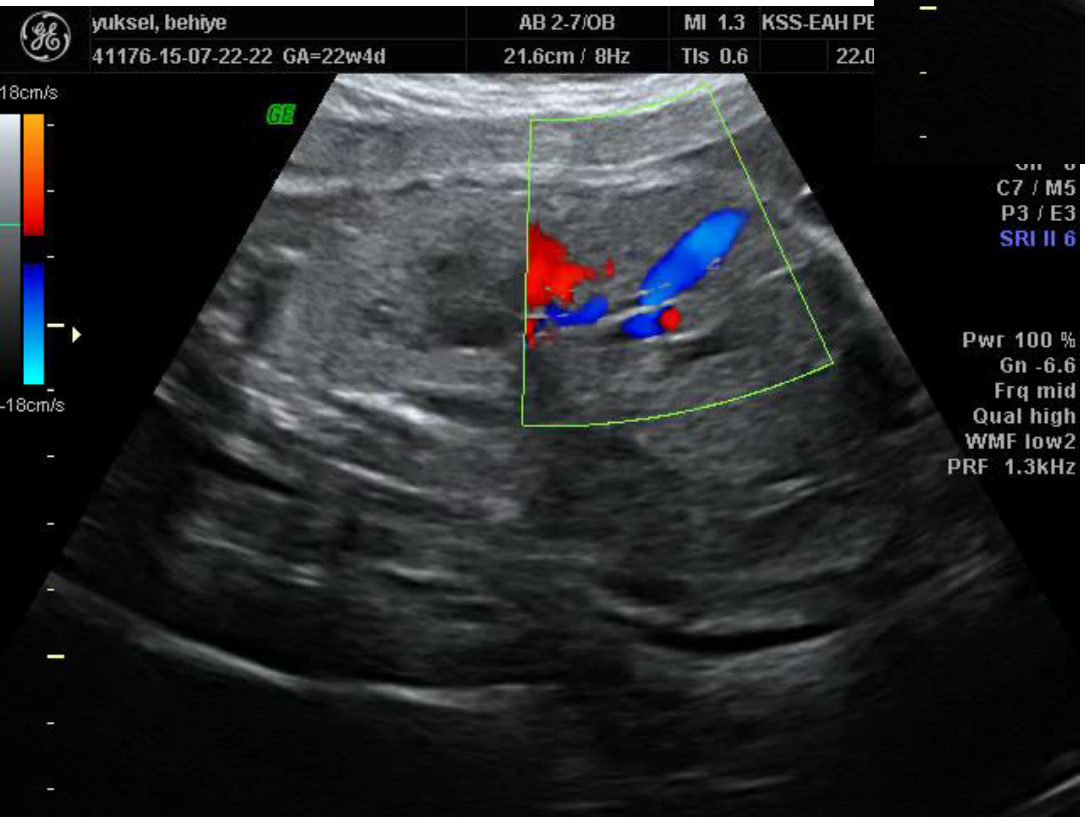
yuksel, behiye
AB 2-7/OB
MI 1.3
41176-15-07-22-22 GA=22w4d
21.6cm / 8Hz
TIs 0.6
18cm/s
-18cm/s
C7 / M5
P3 / E3
SRI II 6
Pwr 100 %
Gn -6.6
Frq mid
Qual high
WMF low2
PRF 1.3kHz

Duktus Venozus Agenezisi

- Eşlik eden anomaliler: %24-65 (Yagel,Ultrasound Obstet Gynecol, 2010)
- Kardiyak anomaliler (%48), GİS, kas-iskelet sistemi
- Anöploidi:%22 (İliescu, Prenat Diagn,2014)
- %25-50'de portal ven agenizisi
- Hidrops ve jeneralize ödem: %33-52
- Konjestif kalp yetmezliği
- Perinatal ölüm

Prognoz

- Eşlik eden anomaliler
- Anöploidi
- Tipi
- Kardiyomegali
- Hidrops
- Ekstrahepatikte portal sistemin gelişimi
- Şant çapı

Ultrasound Obstet Gynecol 2006; **28**: 275–281
Published online 6 July 2006 in Wiley InterScience (www.interscience.wiley.com). **DOI:** 10.1002/uog.2811

Absence of ductus venosus – importance of umbilical venous drainage s

C. BERG*, D. K/ N* and
U. GEMBRUCH

Table 4 Different types of umbilical venous drainage, their associated conditions and outcome in 42 fetuses with continued pregnancies and no or minor associated anomalies (eight cases from the current series and 34 cases retrieved from a review of the literature over the past 10 years[2,6,7,9–22])

	Associated conditions, n	*Alive at latest follow up*, n
Extrahepatic umbilical venous drainage	29*	20
Cardiomegaly	24	16
Hydrops	7*	2
Portal vein agenesis	10	9
Intrahepatic umbilical venous drainage	13	13
Cardiomegaly	2	2
Hydrops	2	2
Portal vein agenesis	1	1

*Significantly associated with intrauterine or postpartum death; $P < 0.05$.

DOI: 10.1002/pd.3889 PRENATAL DIAGNOSIS

ORIGINAL ARTICLE

Absent ductus venosus – outcomes and implications from a tertiary centre

Joseph T. Thomas[1,2*], Scott Petersen[1,2], Robert Cincotta[1,2], Alison Lee-Tannock[1,2] and Glenn Gardener[1,2]

- 89 olgu (22 + literatür) sağkalım: %60
- Efüzyon/hidropsla ilişkili olan izole: %50 (9/18)
- Umbilikal ven drenajından bağımsız 19/89 izole: %100 sağkalım

Ultrasound Obstet Gynecol 2011; 37: 184–190
Published online

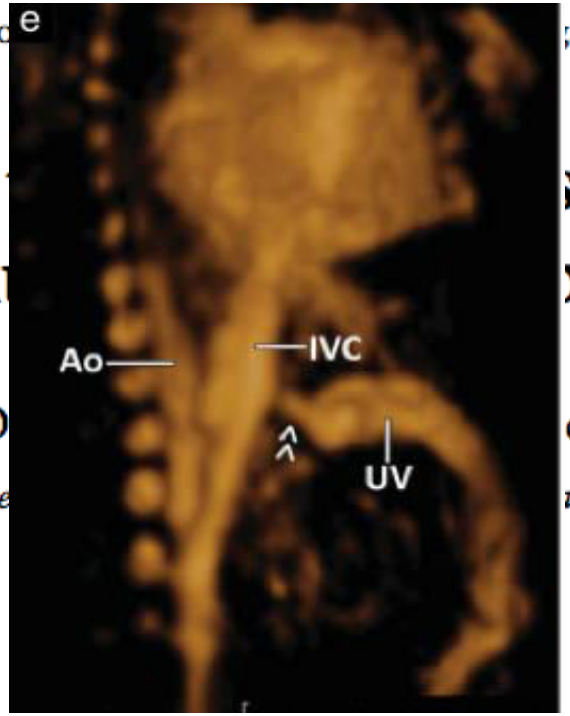

7/22: Şant geniş (En geniş yeri UV'e eşit veya daha geniş). %86 kötü prognoz. 4 ciddi anomali, 2 hepatik disfonksiyon.

15/22: Şant dar (En geniş yeri UV'den dar). %33 kötü prognoz ve hepsinde eşlik eden anomaliler var.

No	Yaş	GH	Umbilikal venin drenajı	Eşlik eden USG bulgusu	Karyotip	Perinatal sonuç
1	29	22	VCİ	Portal sistem agenezisi	46XY,t(1;6)(q23,1;q21)	Terminasyon
2	29	23	VCİ	-	Normal	Sağ, sağlıklı
3	24	18	Sağ atrium	Nazal kemik hipoplazisi, sandal gap, borderline VMG, fırlak topuk, double buble, kardiyomegali	Trizomi 21	Terminasyon
4	30	29	VCİ	-	Normal	Sağ, sağlıklı
5	30	29	VCİ	ACO, TY, TUA, PLVCS	Normal	Neonatal ex
6	32	26	VCİ	AVSD, portohepatik şant, sağ izomerizm	Normal	Terminasyon
7	29	34	Sağ atrium	Bilateral pelviektazi, sağ atrium dilatasyonu, kloaka persistansı	Normal	Sağ, sağlıklı
8	30	16	Sağ atrium	AVSD	Normal	Ulaşılamadı
9	29	23	Sağ atrium	DORV, TPVDA, VSD, TUA, double buble	?	Neonatal ex
10	30	23	Sağ atrium	-	Normal	Sağ, sağlıklı
11	25	23	Sağ atrium	AVSD, duednal atrezi, nazal kemik hipoplazisi, VMG, ense pilisi kalınlığı	Trizomi 21	Terminasyon
12	29	30	VCİ	DORV	?	Neonatal ex
13	36	29	VCİ	-	Normal	Sağ, sağlıklı
14	36	27	VCİ	-	Normal	Sağ, sağlıklı
15	32	24	Sağ atrium	BAT, VSD, komplet AV bloğu	?	Neonatal ex
16	23	37	VCİ	IUGG	Normal	Sağ, sağlıklı

Duktus Venozus Agenezisi

- Detaylı USG ve EKO
- Karyotip analizi
- Ekstrahepatikse portal sistemin gözden geçirilmesi
- Hidrops ve kalp yetmezliği açısından yakın takip
- Postnatal dönemde intrahepatikte porto-sistemik şant, ekstrahepatikte portal sistem agenezisi açısından görüntüleme

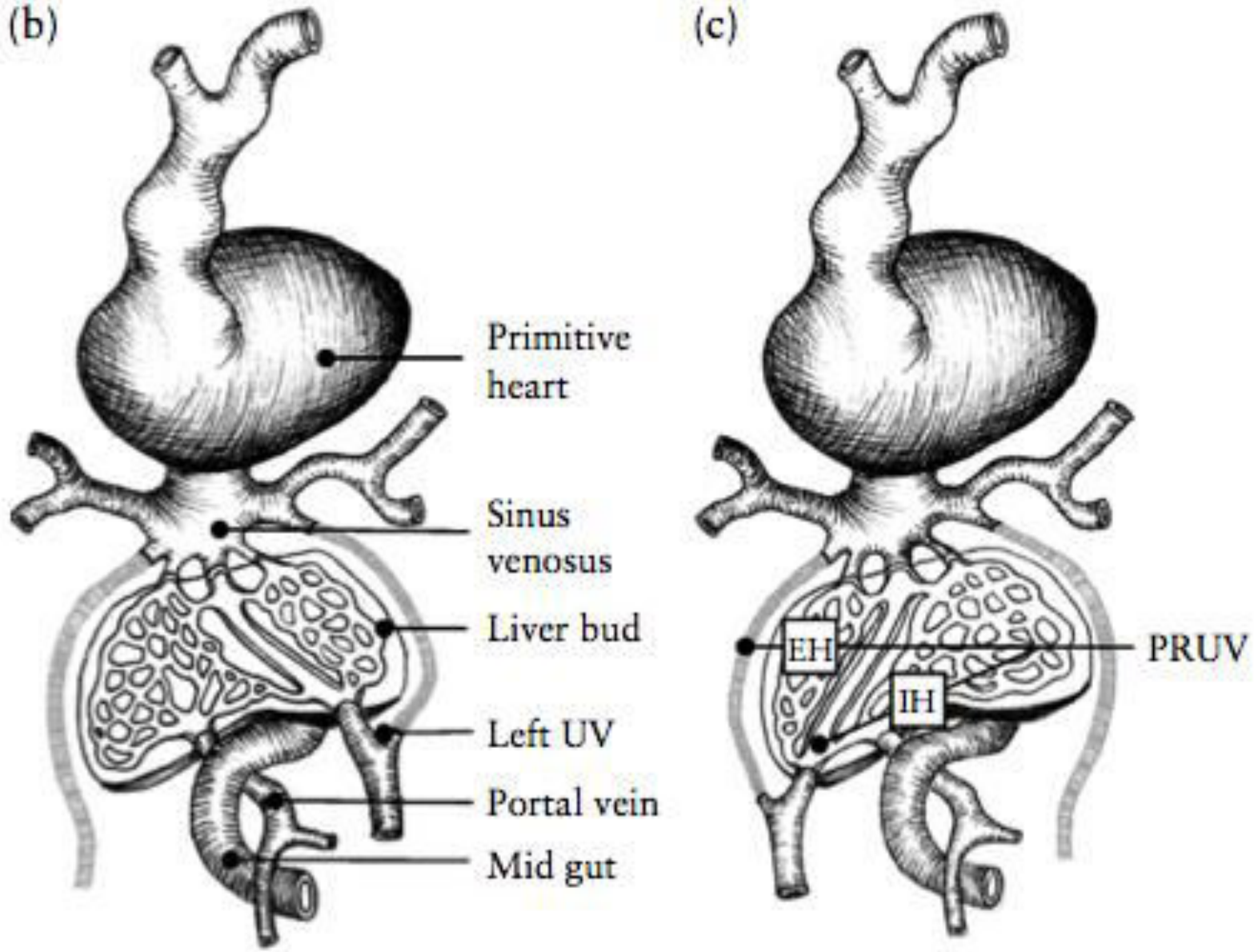
(b)
Primitive heart
Sinus venosus
Liver bud
Left UV
Portal vein
Mid gut
(c)
EH
IH
PRUV

Persistan Sağ Umbilikal Ven

- Prenatal dönemde görülen en sık görülen venöz sistem anomalisi: 1/250-1/1250 (Martinez, Eur J Obstet Gynecol, 2013)
- Teratojenler, bası veya tromboza bağlı olarak erken dönemde sol umbilikal vende obstrüksiyon nedeniyle (Jeanty, Radiology, 1990)
- Retinoik asid ve ya folat alımının az olması da ratlarda PSUV'a yol açmış (Monie, Circ Res, 1957)
- Diğer venlerin veya DV'nin tıkanmasıyla sekonder olarak da oluşabilir

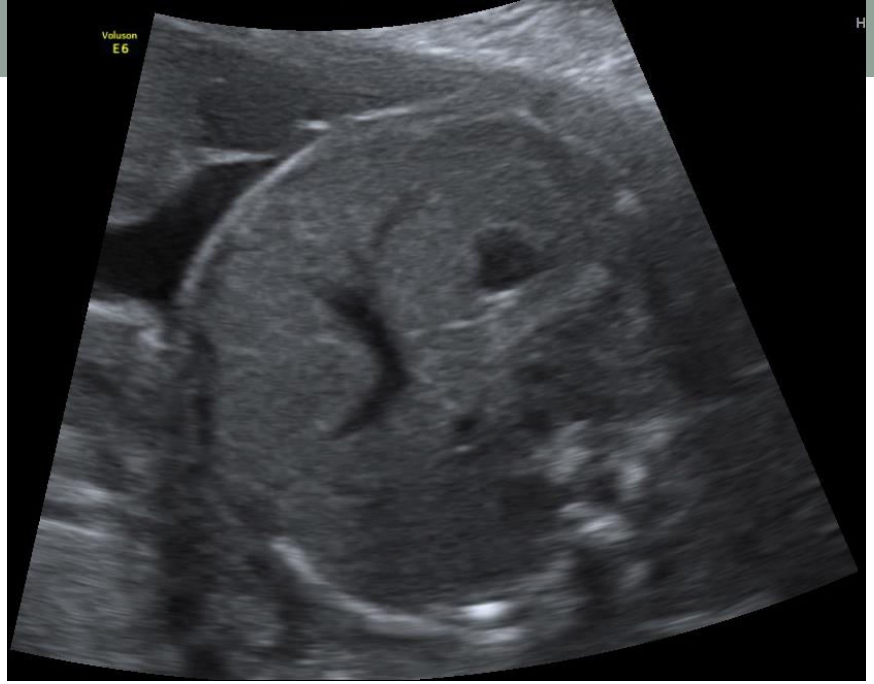
Voluson
E6

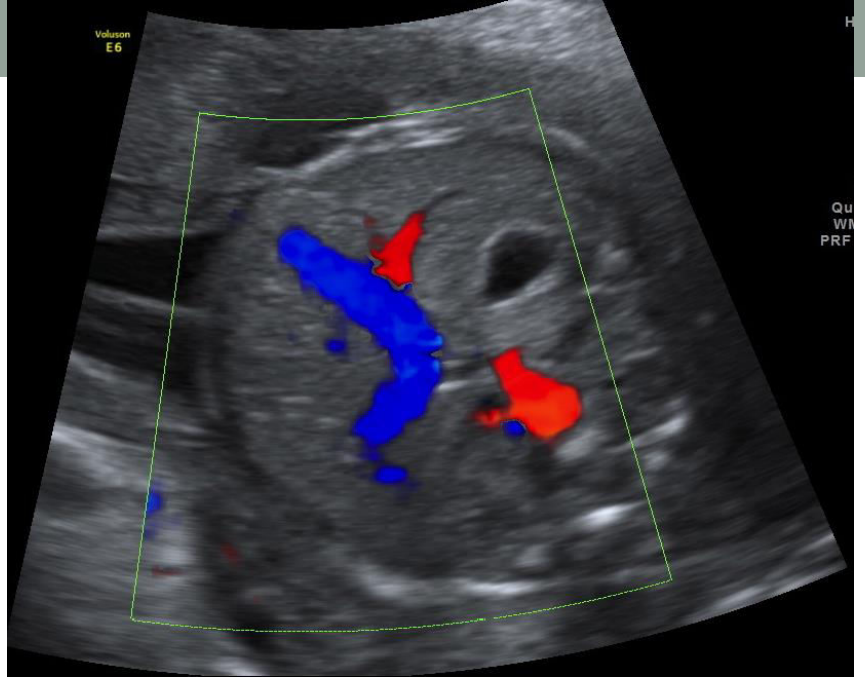
Voluson
E6

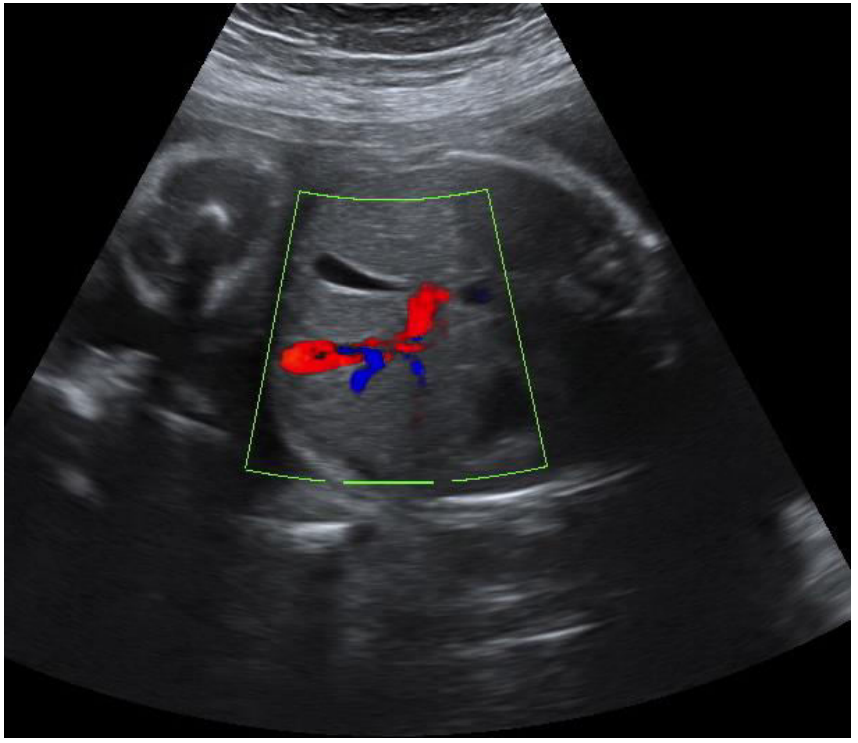

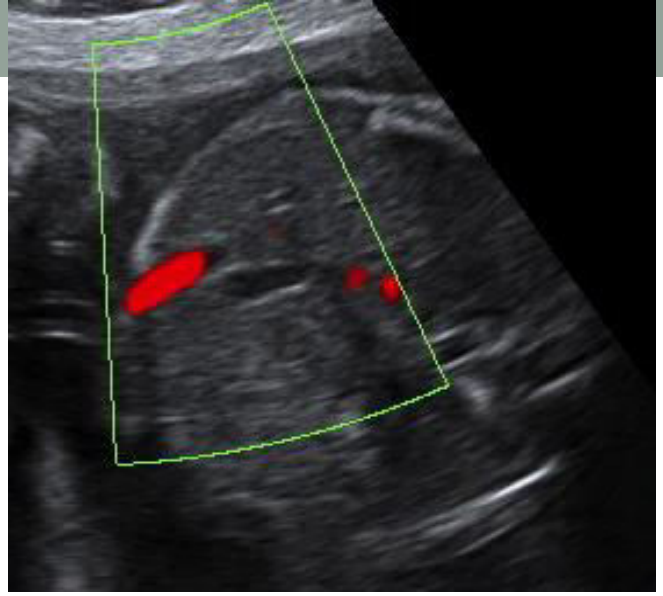

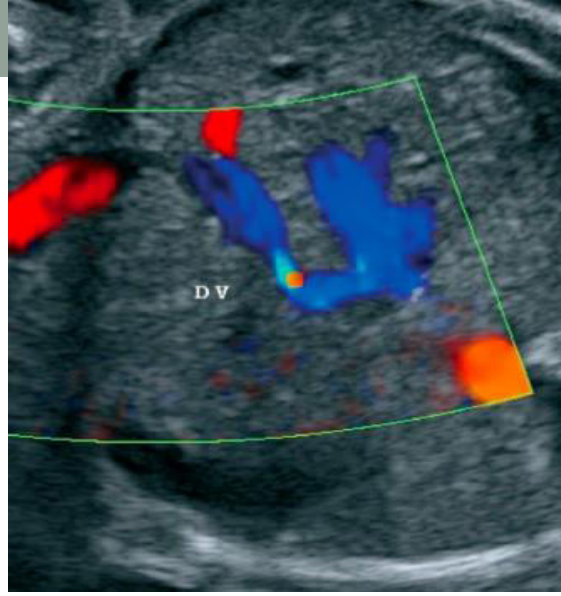
DV

celik, pinar
AB 2-7/OB
MI 1.3
KSS-EAH PERINATOLOJI
41176-15-10-09-17 GA=23w2d
16.8cm / 15Hz
TIs 0.1
09.10.2015 15:04:40
1. Trim.
Har-high
Pwr 100 %
Gn 0
C7 / M5
P3 / E3
SRI II 6
GE

Ultrasound Obstet Gynecol 2011; 37: 543–548
Published online 25 March 2011 in Wiley Online Library (wileyonlinelibrary.com). **DOI:** 10.1002/uog.7764

Persistent right umbilical vein: a prenatal condition worth mentioning?

J. WEICHERT*, D. HARTGE*, U. GERMER†, R. AXT-FLIEDNER‡ and U. GEMBRUCH§

**Division of Prenatal Medicine, Department of Gynecology and Obstetrics, University Hospital of Schleswig-Holstein, Campus Luebeck, Germany; †Department of Obstetrics and Gynecology, Caritas Hospital St. Josef, Regensburg, Germany; ‡Department of Obstetrics and Gynecology, Division of Prenatal Medicine, University of Giessen, Giessen, Germany; §Department of Obstetrics and Prenatal Medicine, University of Bonn, Bonn, Germany*

- 302 olgu (39 + literatür)
- %25.2 (66) eşlik eden anomali var
- En çok CVS, GIS ve GUS
- %94.7 intrahepatik tip: Yapısal anomali %21
- İzolelerde anöploidi %0.3, izole olmayanlarda %1.6
- %5.3 (16) ekstrahepatik tip: Anöploidi %18, yapısal anomali %100

Persistan sağ umbilikal ven

- %30 İUGG (%46 izole, %22 izole olmayanda) (Martinez, Eur J Obstet Gynecol,2013)
- Detaylı USG + EKO, fetal büyüme takibi
- Prognoz ek anomaliye bağlı (Mubiayi, J Gynecol Obstet Biol Reprod, 2003)
- İzoleyse ve DV ile düzgün bir anastamoz yapılmışsa klinik önemi yok. Normal varyant.
- İzole PRUV-İ'de karyotip analizine gerek yok
- İzole PRUV-E'de karyotip analizi gerekli

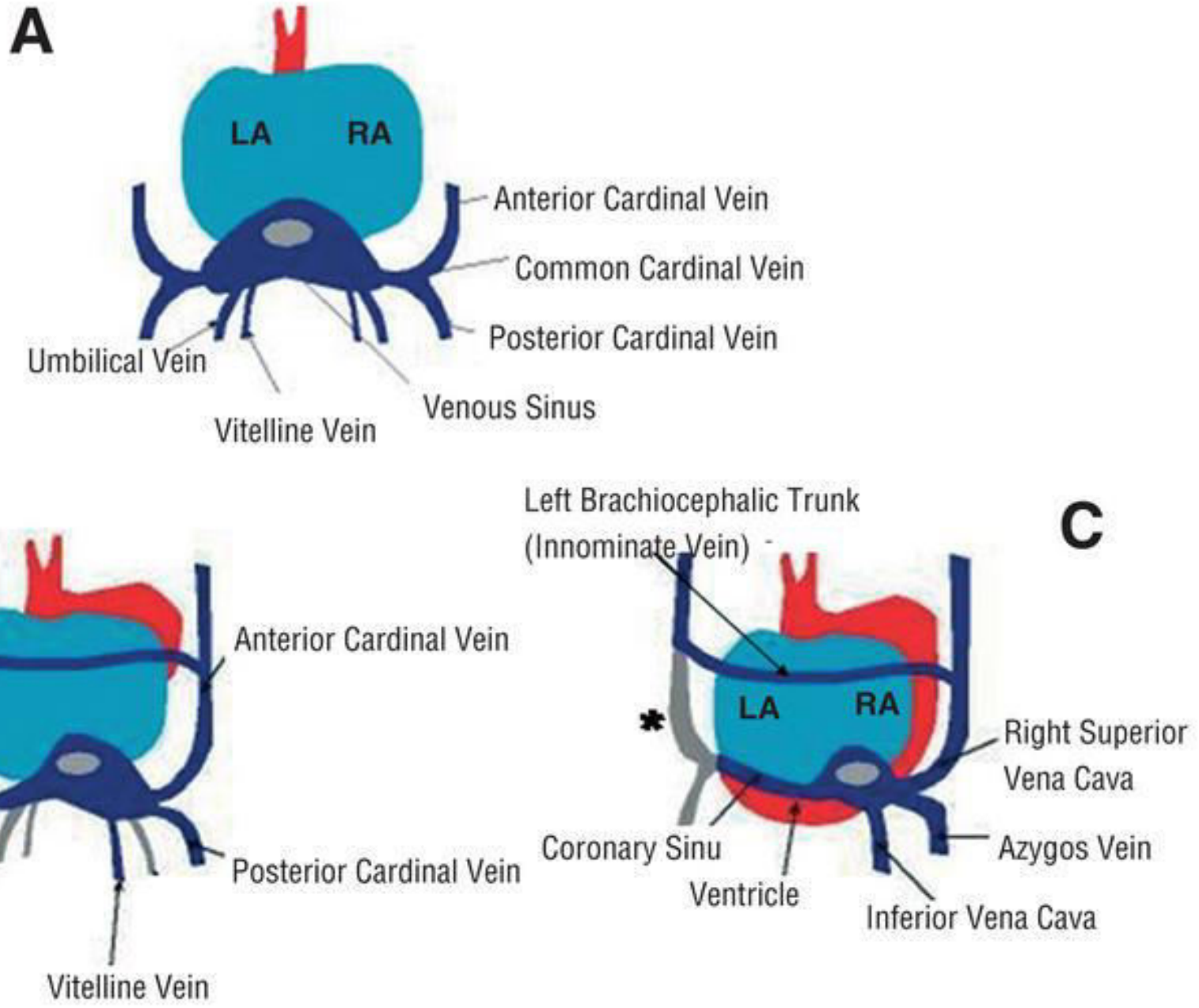
A
LA
RA
Anterior Cardinal Vein
Common Cardinal Vein
Posterior Cardinal Vein
Umbilical Vein
Vitelline Vein
Venous Sinus
B
Anterior Cardinal Vein
Posterior Cardinal Vein
Vitelline Vein
C
Left Brachiocephalic Trunk
(Innominate Vein)
LA
RA
Right Superior
Vena Cava
Azygos Vein
Coronary Sinu
Ventricle
Inferior Vena Cava

Persistan Sol Superior Vena Cava

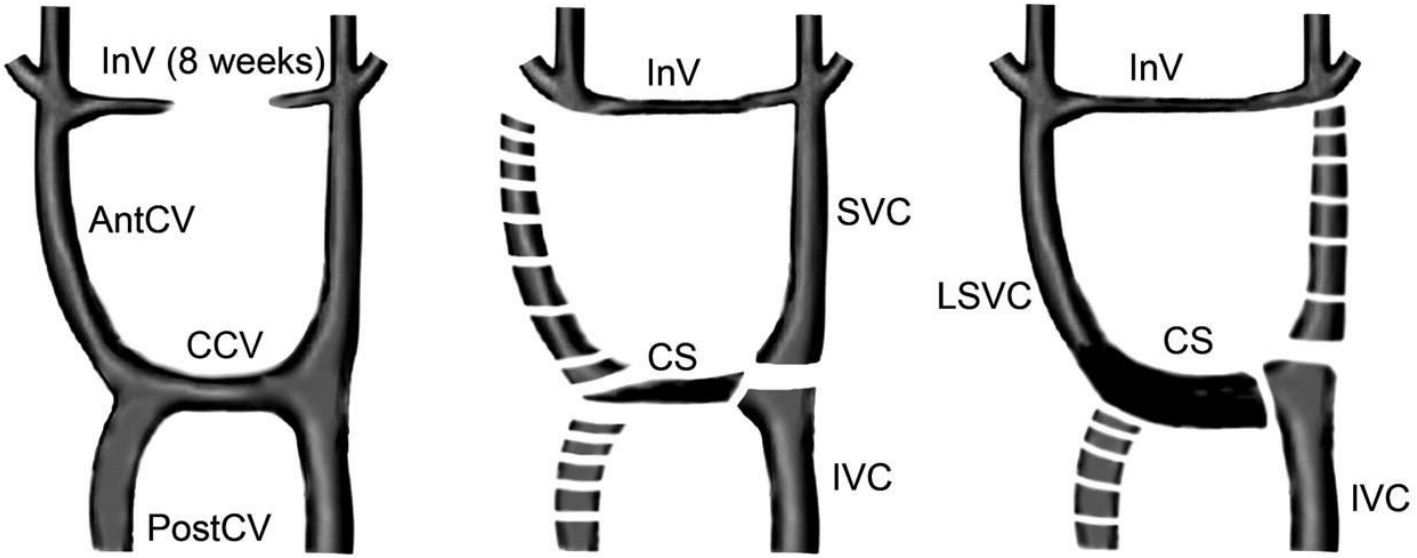

- Kardiyak malformasyon yoksa %0.3, varsa %4 (Biffi, Chest, 2001)
- Fetuslarda %0.2 ve %9 ve CHD için OR: 49.9 (Galindo, Ultrasound Obstet Gynecol 2007).
- %90 koroner sinüsle sağ atriuma, %10 sol atriuma

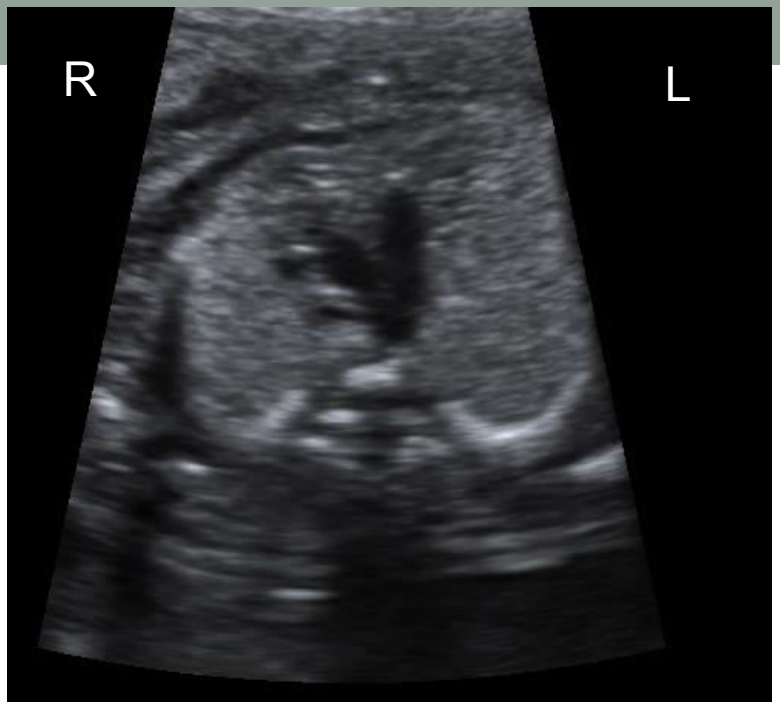
R
L

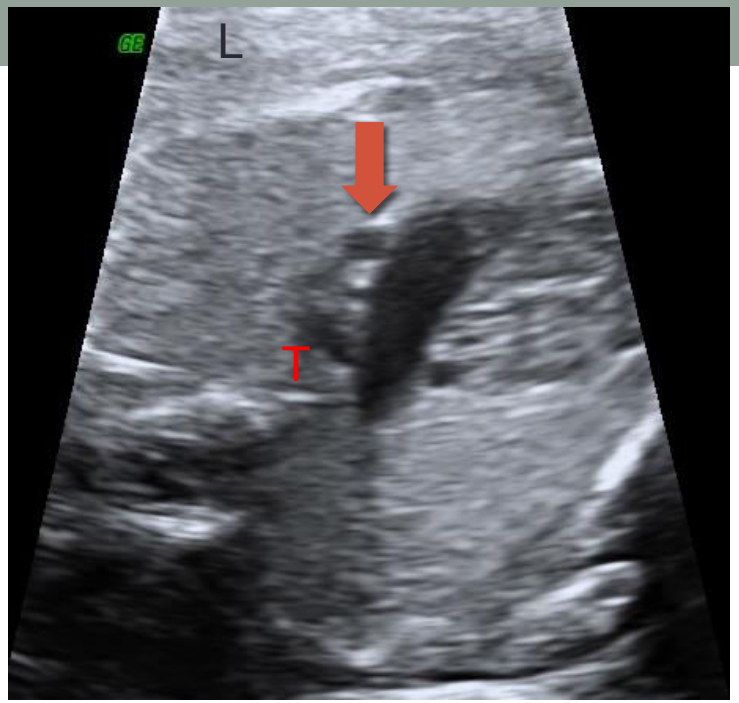
GE
L
T

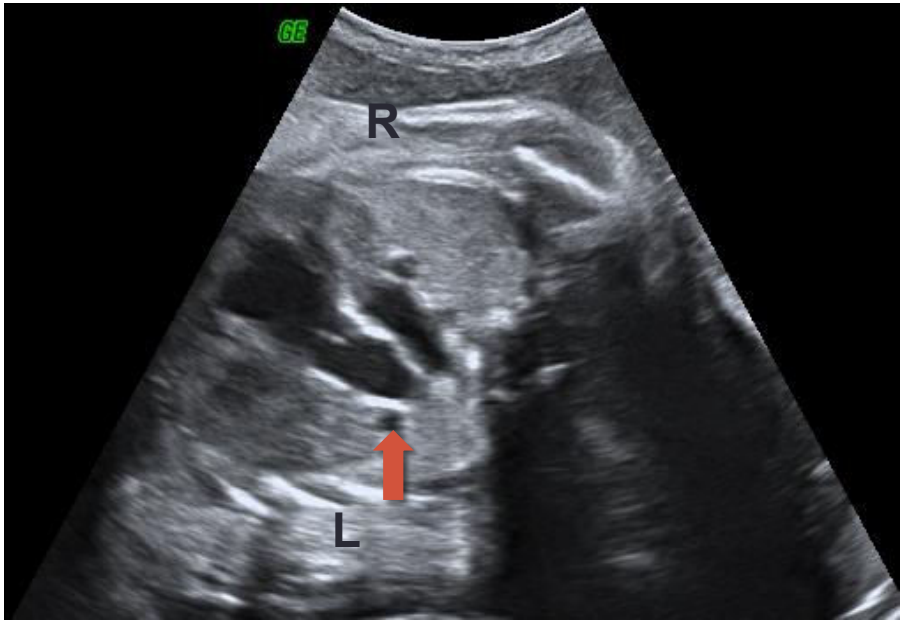
GE
R
L

tagay, bilnaz
AB 2-7/OB
MI 1.3
KSS-EAH PERINATOLOJI
41176-15-08-12-7 GA=35w5d
18.4cm / 16Hz
TIs 0.2
12.08.2015 10:01:30
2+3.Trim.
Har-high
Pwr 100 %
Gn 5
C7 / M5
P3 / E3
SRI II 6
GE

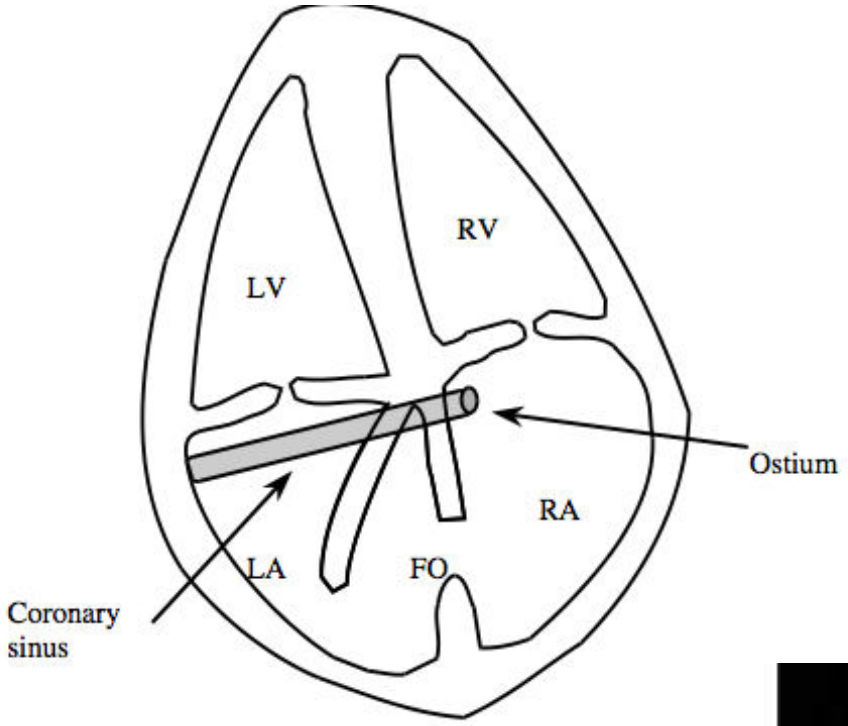

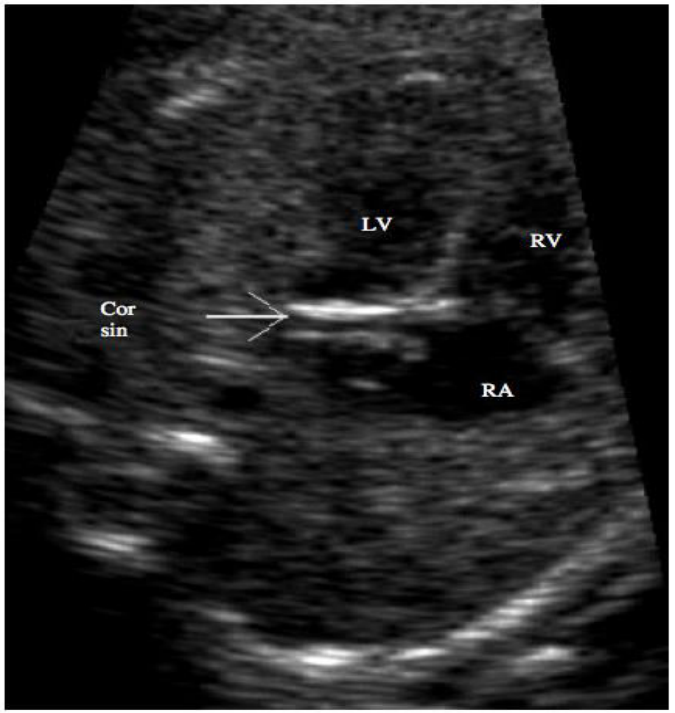

20. hf-term: 1.2-2.7 mm
LSVC'de 2.7-6.5 mm

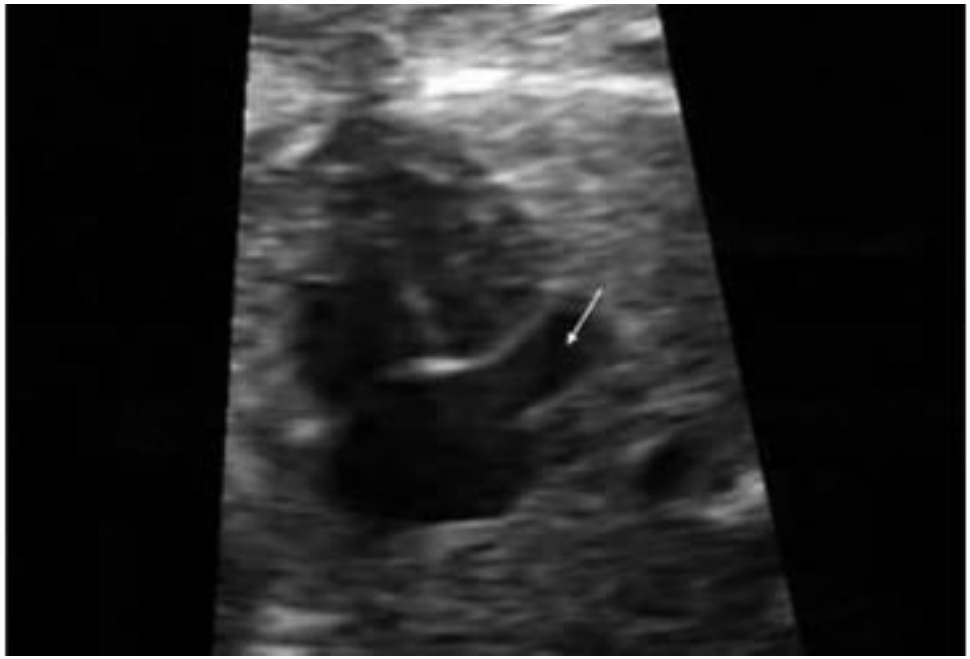

Persistan Sol Superior Vena Cava

- Ayırıcı tanı:

Primum tipi atriyal septal defekt

Mitral atrezi: Mitral kapak koroner sinüs tarafından öne itilir

Anormal pulmoner venöz dönüş de koroner sinüste dilatasyona yol açar

Ventrikül diskordansında düşünülmeli

Persistan Sol Superior Vena Cava

- Prognoz eşlik eden anomalilere bağlı
- %81.4 kardiyak, %5.5 izole

(Galindo, Ultrasound Obstet Gynecol, 2007)

- %83 kardiyak, %23 izole kardiyak, %7 izole ekstrakardiyak, %9 izole (Berg,Ultrasound Obstet Gynecol, 2006)
- Kardiyak: AVSD, DORV, sol çıkış obstrüksiyonu, konotrunkal anomaliler, VSD
- Ekstrakardiyak: Heterotaksi, ösefagus atrezisi, diyafram hernisi, IVC malformasyonları, kompleks malformasyon sendromları, kromozom anomalileri

(Yagel, Obstet Gynecol, 2010)

Persistan Sol Superior Vena Cava

- Karyotipleme tartışmalı
- %9, ama eşlik eden bulgu var

(Galindo, 2007 ve Berg, 2006)

- Eşlik eden anomalileri gözden kaçırıyor olabiliriz

(Kalache, Prenant Diagn, 2003)

- 5/15 kromozom anomalisi. Biri izole - T 21

(Barrea, Prenat Diagn, 2011)

Contents lists available at ScienceDirect

Taiwanese Journal of Obstetrics & Gynecology

journal homepage: www.tjog-online.com

Research Letter

Prenatal diagnosis of mosaic tetrasomy 9p in a fetus with isolated persistent left superior vena cava

Hao Wang [a], Le-Si Xie [b], Yan Wang [a], Jin Mei [a,*]

[a] Prenatal Diagnosis Center, Hangzhou Maternity and Child Care Hospital, Hangzhou, Zhejiang, China
[b] Department of Pathology, Hangzhou First People's Hospital, Hangzhou, Zhejiang, China

ARTICLE INFO

Article history:
Accepted 10 December 2014

A healthy 36-year-old, gravida 2, para 1, woman was referred for noninvasive prenatal testing (NIPT) at 17 weeks of gestation because of an advanced maternal age. From her first pregnancy she give birth to a now 9-year-old healthy boy and the present pregnancy had been uneventful to date. NIPT revealed "extra genetic material derived from chromosome 9" and amniocentesis was recommended. An extra chromosome (Fig. 1A) was identified in 6 out of 38 amniocytes, and the mosaicism was later confirmed in cord blood lymphocytes, with a higher ratio (34 out of 57 cells) of

cases. A review of 20 well-documented cases of i(9p) by Tonk [2] revealed a pattern of recurring features, including ear malformations, skeletal and joint problems (especially dislocations), hypoplasia of nails and digits, palatal abnormalities, hypertelorism,

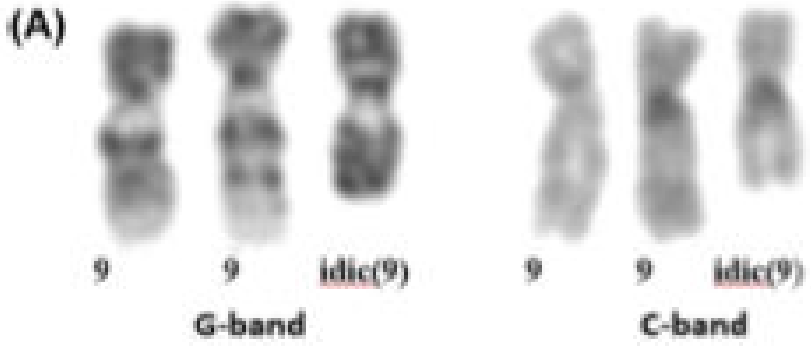

Copyright © Trakya University Faculty of Medicine
Balkan Med J 2014;31:50-54 © 2014

Prenatal Diagnosis of Persistent Left Superior Vena Cava and its Clinical Significance

Aytül Çorbacıoğlu Esmer[1], Atıl Yüksel[2], Halime Çalı[1], Mehmet Özsürmeli[1], Rukiye Eker Ömeroğlu[2], İbrahim Kalelioğlu[1], Recep Has[1]

[1]Department of Obstetrics and Gynecology, İstanbul University Faculty of Medicine, İstanbul, Turkey
[2]Department of Pediatric Cardiology, İstanbul University Faculty of Medicine, İstanbul, Turkey

Background: Persistent left superior vena cava (PLSVC) is a variant of systemic venous return which is observed in 0.3% of autopsies in the general population and in 4-8% of patients with congenital heart disease.
Aims: To evaluate associated cardiac, extracardiac and chromosomal anomalies in prenatally diagnosed cases of PLSVC and to review their outcome.
Study Design: Retrospective comparative study.
Methods: The data of patients with a prenatal diagnosis of PLSVC between May 2008 and January 2013 were reviewed retrospectively.
Results: Data of 31 cases were reviewed. Fifteen (48.4%) cases were associated with cardiac defects and 17 (54.8%) cases had associated extracardiac sonographic or postpartum findings. Two fetuses had karyotype anomalies. Outcome was significantly more favorable in cases not associated with cardiac defects in comparison to those associated with cardiac anomalies (84.6% vs. 33.3%, p=0.009). All cases with isolated PLSVC survived, while among the cases associated with extracardiac anomalies, with cardiac anomalies and with both extracardiac and cardiac anomalies, the survival rate was 75%, 50% and 22.2%, respectively. The most frequent group of cardiac anomalies associated with PLSVC was septal defects and VSD was the most common heart defect individually, being observed in nine fetuses.
Conclusion: Prenatally diagnosed PLSVC is associated with cardiac and extracardiac anomalies in the majority of cases. Outcome is significantly worse if PLSVC is associated with a cardiac defect, and the prognosis is excellent in isolated cases.
(*Balkan Med J* 2014;31:50-54).
Key Words: Cardiac anomaly, congenital anomaly, persistent left superior vena cava, prenatal diagnosis, ultrasound

Persistan Sol Superior Vena Cava

- Sağ SVC yoksa erişkinlikte sorun olabilir:
  - Girişim zor olabilir (transvenöz pacemaker, pulmoner arter katetirazasyonu, kardiyak bypass için sistemik venöz kanulasyon)
  - Koroner sinüs dilatasyonuna bağlı disritmi gelişebilir
- Holter ve EKO'yla takip önerilir. (Guarnieri, Pediatr Cardiol, 2006)

TEŞEKKÜRLER…